



## PATIENT PRESENTING CLINICAL SIGNS

- Carlos Alesandro
- Greyhound lameness right thoracic limb
  - Weight bearing but lame

## SPECIES RADIOGRAPHIC STUDY OF THE RIGHT FRONT PAW

Canine Mediolateral and craniocaudal views of the right front paw totaling 2 images are available for review.

## RADIOGRAPHIC FINDINGS

### BREED

Greyhound

Minimal smooth periarticular new bone formation is seen on the dorsal aspect of the right carpometacarpal joint.

Minimal soft tissue swelling is present around the third digit.

### SEX

MN

A bipartite axial sesamoid bone is noted at the metacarpophalangeal joint of the fifth digit in the right front paw.

No aggressive lesions, fractures or significant osteoarthritis is seen.

### AGE

9.5yr

## RADIOGRAPHIC DIAGNOSIS

- Mild chronic degenerative changes in the right carpometacarpal joint, bipartite axial sesamoid bone, fifth metacarpophalangeal joint
- Minimal soft tissue swelling of the third digit

## INTERPRETED BY

Nele Eley (Ondreka),  
DVM Dr. med. vet.,  
DipECVDI

## INTERPRETATION OF FINDINGS & FURTHER RECOMMENDATIONS

The mild changes observed may not fully explain the degree of lameness, especially in a greyhound where subtle soft tissue or tendon injuries may cause clinical signs without obvious radiographic findings. Clinical correlation is recommended to evaluate for soft tissue injury as well as potential neurologic disease or orthopedic disease from different anatomic locations. MRI could be considered for further definition if lameness persists or worsens depending on the clinical concern and correlation.

## HOSPITAL NAME

New Bridge  
Veterinary Practice

## REFERRING VET

Dr Glennon

## INVOICE

24116

## DATE

03/04/2026



## PATIENT

Carlos Alesandro

## SPECIES

Canine

## BREED

Greyhound

## SEX

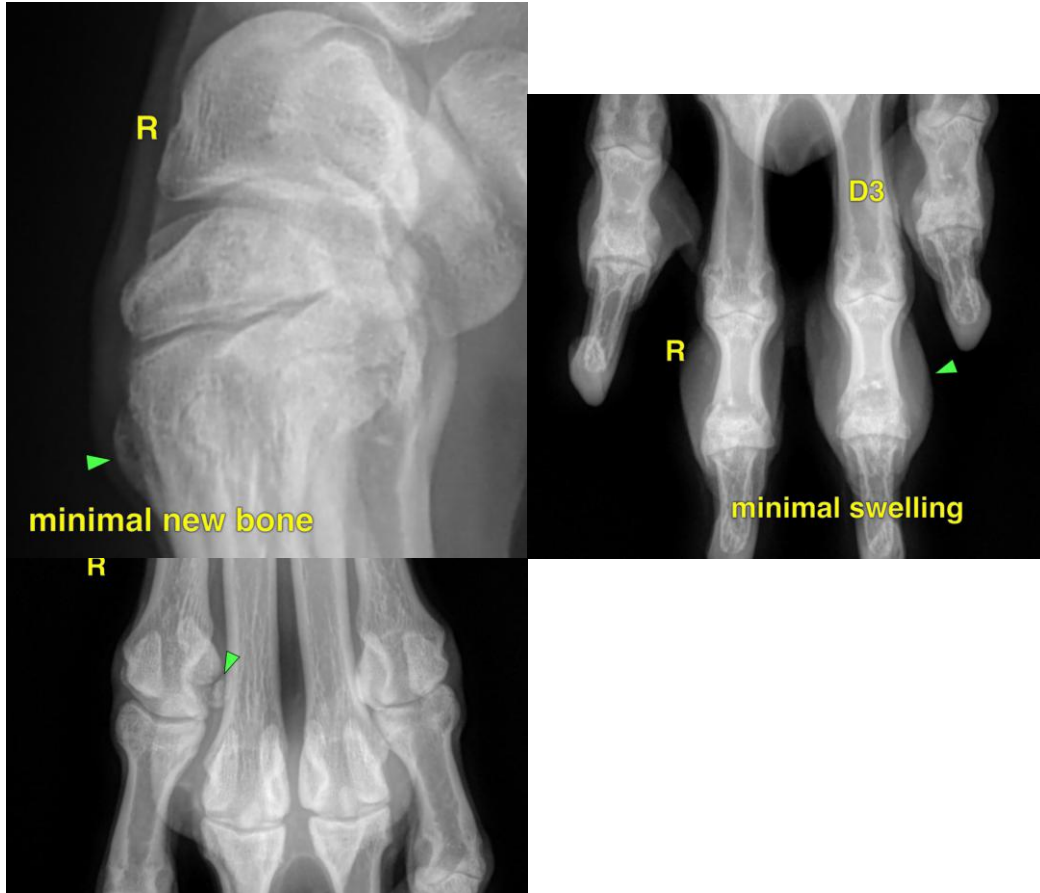
MN

## AGE

9.5yr

## INTERPRETED BY

Nele Eley (Ondreka),  
DVM Dr. med. vet.,  
DipECVDI



## HOSPITAL NAME

New Bridge  
Veterinary Practice

The information and recommendations provided are based on the images presented by the referring veterinarian. No evaluation can be communicated regarding pathology that was not visible in the image/video clips provided.

Thank you for this referral. If the clinical or image interpretation does not parallel your findings or if I can be of any further assistance please contact me.

## REFERRING VET

Dr Glennon

Nele Eley (Ondreka), DVM, Dr. med. vet., DipECVDI  
European Specialist in Veterinary Diagnostic Imaging, Cert. Radiology,  
Senior lecturer University of Giessen/Germany, Veterinary Faculty, Department of Radiology.  
[info@sonopath.com](mailto:info@sonopath.com)

## INVOICE

24116

## DATE

03/04/2026



## PATIENT

Carlos Alesandro

## SPECIES

Canine

## BREED

Greyhound

## SEX

MN

## AGE

9.5yr

## INTERPRETED BY

Nele Eley (Ondreka),  
DVM Dr. med. vet.,  
DipECVDI

## HOSPITAL NAME

New Bridge  
Veterinary Practice

## REFERRING VET

Dr Glennon

## INVOICE

24116

## DATE

03/04/2026